



	Experiment title: Cerebral angiography in an rabbit model	Experiment number: MD-117
Beamline:	Date of experiment: from: Nov. 05 to: Nov. 9, 2004	Date of report: January 12, 2005
Shifts:	Local contact(s): Dr. Stephanie Corde	<i>Received at ESRF:</i>
Names and affiliations of applicants (* indicates experimentalists): Dr. Elisabeth Schültke, Liverpool University, U.K. and University of Saskatchewan * Dr. Kotoo Meguro, University of Saskatchewan, Canada * Dr. Michael Kelly, University of Saskatchewan, Canada * Dr. Lissa Ogieglo and Dr. Lauren Allen, University of Saskatchewan, Canada * Dr. Andrea Lavoie, New Halifax Infirmary, Halifax, Canada * Dr. Stefan Fiedler, EMBL, Germany * Dr. Christian Nemoz, ESRF, France * Dr. Geraldine LeDuc, ESRF, France Dr. Francois Esteve, INSERM- U647 ESRF, France		

Report:

The experiments conducted during the beamtime allocated for MD-117 continued our investigation whether intravenous K-edge digital subtraction angiography (KEDSA) could become a feasible diagnostic approach for neurovascular pathology or for vascular pathology of the extremities. Experiments were split into two sections: Section 1 was aimed at image acquisition of cerebral and spinal vasculature as well as vasculature of the heart and extremities in healthy animals. Section 2 was designed for the study of pathology of the cerebral vasculature after subarachnoid hemorrhage. All experiments were conducted in adult male New Zealand rabbits (8) as experimental subjects.

Experiments for section 1: Planar and CT angiograms of cerebral and spinal vasulature were acquired with a moderate resolution (350 micron) Germanium detector to reproduce results from the previous experimental cycle (MD-75). Since the control software and associated hardware (fast beam chopper) for the FRELON camera had been significantly improved since our last experiments (also it is not yet optimal for our purposes), we were able

to acquire a second set of cerebral and vascular images, taking advantage of the higher resolution provided by the FRELON camera (Figure 1). Finally, a set of vascular images of the pelvis and hindlimbs as well as of the heart were acquired in planar projection with the Ge detector. For comparison of image quality, angiographic images were also acquired with conventional X-ray equipment (Philips BV 212 C-arch).

Experiments for section 2: Two researchers arrived two days before the beginning of the beamtime in order to prepare the animal experiments for the study of neurovascular pathology. We chose a model of subarachnoid hemorrhage, a frequent indication for cerebrovascular angiography, in which vascular spasms (temporary narrowing of the vascular lumen) frequently develops several days after the hemorrhage has taken place. Arterial blood taken from an ear artery was injected into the cisterna magna of two anesthetized animals. The animals were then allowed to recover until they were subjected to the imaging experiments. Images of cerebral vasculature were acquired in both planar and CT modes with Germanium detector and FRELON camera.

All KEDSA images were acquired after intravenous injection of iodinated contrast agent (Iomeron 350).

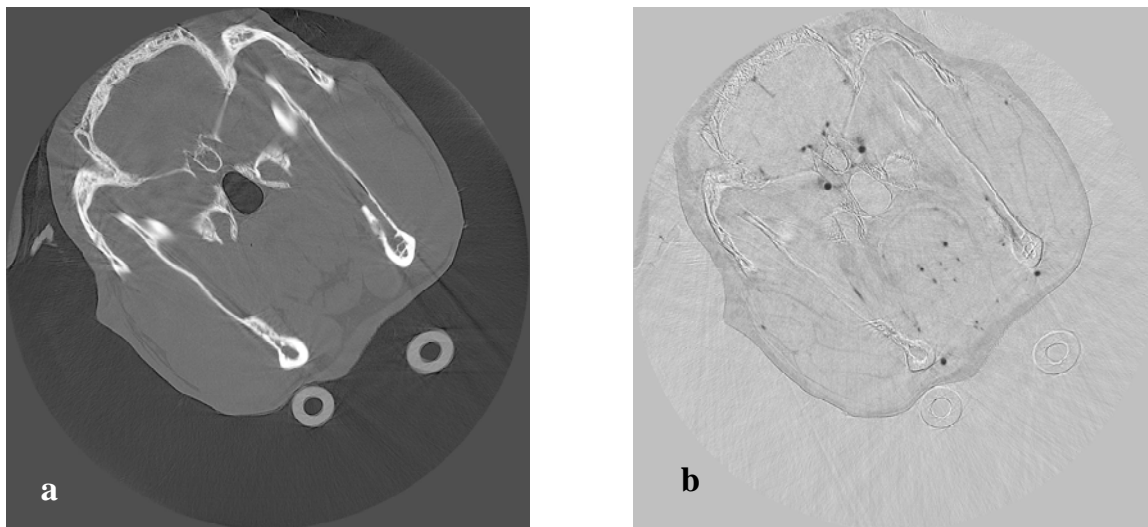


Figure 1:

CT angiography image of rabbit head, acquired with FRELON camera.

Reconstructed tissue image, no contrast injection (a) and K-edge subtraction image after contrast injection (b)

We very much enjoyed the working atmosphere at ID 17 and therefore wish to further develop the techniques (models and acquisition procedures) in collaboration with the ID 17 team. In future experiments, we wish to test our hypotheses that a) visualization of cerebral and spinal vasculature is also possible in larger experimental subjects (i.e.pigs) and b) that the diameter of the smallest detectable blood vessel is equal regardless of the size of the animal. If those experiments would yield positive results, synchrotron-supported K-edge subtraction angiography might become a good alternative diagnostic technique in cases of human vascular pathology that are difficult to diagnose with presently used angiographic imaging techniques.

Our special thanks go to Mr. Dominique Dallery for his expertise in all matters concerning the care for our animals. We also wish to thank everybody who helped organizing 'behind the scenes' to make our experiments successful.

Our first paper resulting from the neurovascular experiments conducted at ID 17 has been submitted to *NIMA* :

Schültke, Fiedler et al.: The Potential for Neurovascular Intravenous Angiography using K-Edge Digital Subtraction Angiography.

A second paper is going to be submitted shortly to *J Neurosurgery*:

Kelly, Fiedler et al.: Synchrotron-BASED intravenous cerebral angiography in a small animal model.

Poster presentations were made at the 7th CLS Users' Meeting in Saskatoon, Canada, Nov. 04:

Schültke, Fiedler et al.:

Neurovascular imaging using synchrotron-based K-Edge digital subtraction angiography.

and will be made at the CCNS Meeting in Ottawa, Canada, in June 2005:

Ogieglo, Fiedler et al.:

Developing an animal model for synchrotron-based neurovascular research.

Abstracts and references for publications will be submitted once they have been accepted and go into print. Abstracts of posters or oral presentations that will be reprinted in scientific journals will also be forwarded to the ESRF User Office.