



Experiment Report Form

The double page inside this form is to be filled in by all users or groups of users who have had access to beam time for measurements at the ESRF.

Once completed, the report should be submitted electronically to the User Office via the User Portal:

<https://www.esrf.fr/misapps/SMISWebClient/protected/welcome.do>

Deadlines for submission of Experimental Reports

Experimental reports must be submitted within the period of 3 months after the end of the experiment.

Experiment Report supporting a new proposal (“relevant report”)

If you are submitting a proposal for a new project, or to continue a project for which you have previously been allocated beam time, you must submit a report on each of your previous measurement(s):

- even on those carried out close to the proposal submission deadline (it can be a “*preliminary report*”),
- even for experiments whose scientific area is different from the scientific area of the new proposal,
- carried out on CRG beamlines.

You must then register the report(s) as “relevant report(s)” in the new application form for beam time.

Deadlines for submitting a report supporting a new proposal

- 1st March Proposal Round - **5th March**
- 10th September Proposal Round - **13th September**

The Review Committees reserve the right to reject new proposals from groups who have not reported on the use of beam time allocated previously.

Reports on experiments relating to long term projects

Proposers awarded beam time for a long term project are required to submit an interim report at the end of each year, irrespective of the number of shifts of beam time they have used.

Published papers

All users must give proper credit to ESRF staff members and proper mention to ESRF facilities which were essential for the results described in any ensuing publication. Further, they are obliged to send to the Joint ESRF/ ILL library the complete reference and the abstract of all papers appearing in print, and resulting from the use of the ESRF.

Should you wish to make more general comments on the experiment, please note them on the User Evaluation Form, and send both the Report and the Evaluation Form to the User Office.

Instructions for preparing your Report

- fill in a separate form for each project or series of measurements.
- type your report in English.
- include the experiment number to which the report refers.
- make sure that the text, tables and figures fit into the space available.
- if your work is published or is in press, you may prefer to paste in the abstract, and add full reference details. If the abstract is in a language other than English, please include an English translation.



	Experiment title: Evaluating microstructural damage in unstained ovarian endometrial and liver tissues with speckle-based phase-contrast and dark-field CT	Experiment number: MD-1378
Beamline: ID19	Date of experiment: from: 08 June 2023 to: 12 June 2023	Date of report: 30/08/2023
Shifts: 12	Local contact(s): Ludovic Broche	<i>Received at ESRF:</i>
Names and affiliations of applicants (* indicates experimentalists): Ms. Lautizi Ginevra (*), University of Trieste and Elettra Sincrotrone Ms. Pascolo Lorella (*), Ospedale Burlo Garofalo Dr. De Marco Fabio (*), University of Trieste and Elettra Sincrotrone Dr. Di Trapani Vittorio (*), University of Trieste and Elettra Sincrotrone Ms. Savatović Sara (*), University of Trieste and Elettra Sincrotrone Mr. Margini Marco (*), University of Trieste and Elettra Sincrotrone Prof. Dr. Pierre Thibault, University of Trieste and Elettra Sincrotrone		

Report:

Introduction and motivation:

This experiment aimed at performing X-ray speckle-based tomography on ovarian, endometrial, and liver tissues. This study allowed us to understand the local changes in the microstructures resulting from a specific pathology (endometriosis, steatosis), and a cryopreservation procedure (vitrification). To that end, X-ray speckle-based imaging (SBI) has been used, due to its high sensitivity to small density differences in unstained soft tissues. Unlike other techniques, SBI also provides additional information about small-angle scattering, known as dark-field. Dark-field signal was used to improve the visualisation of sub-resolution microstructure alterations and to quantitatively detect the orientation of anisotropic structures.

Results so far:

From a combined analysis of phase and dark-field tomograms, we were able to identify the local changes in the microstructures of unstained tissues as well as to detect sub-resolution alterations caused by specific pathologies.

Several samples included in different materials (paraffin, ethanol, osmium, tissuetek) have been scanned: human liver with steatosis from patients of different ages, and bovine and human ovaries with endometriosis. Both high-resolution and medium-resolution scans were performed, with a pixel size of 1.3 μm and 3.1 μm , respectively. The main problem was the strong absorption at 19 keV of liver samples, therefore we had to change the energy to 26.5 keV to minimise radiation damage effects.

In Fig. 1, two X-ray phase-contrast axial slices are shown as a result of a preliminary analysis, both with high-resolution set-up. On the left-hand side, a ROI of a virtual slice of a human liver sample in ethanol. Lipidic aggregates are clearly visible as dark circles. On the right-hand side, a ROI of a virtual slice of a bovine ovary. Follicles are visible and conclusions about cryopreservation protocol's effectiveness can be drawn by looking at the regions near ova.

A further analysis of the data is currently ongoing.

Conclusions:

The findings in this field could be applied to enhance procedures for preserving fertility, especially for young women and prepubertal girls who face the risk of infertility due to chemotherapeutic treatments. Additionally, through dark-field analysis of liver tissue, we were able to identify sub-micrometer lipid aggregates that would otherwise remain invisible. With this study, we were able to make an unparalleled assessment of the extent of steatosis severity.

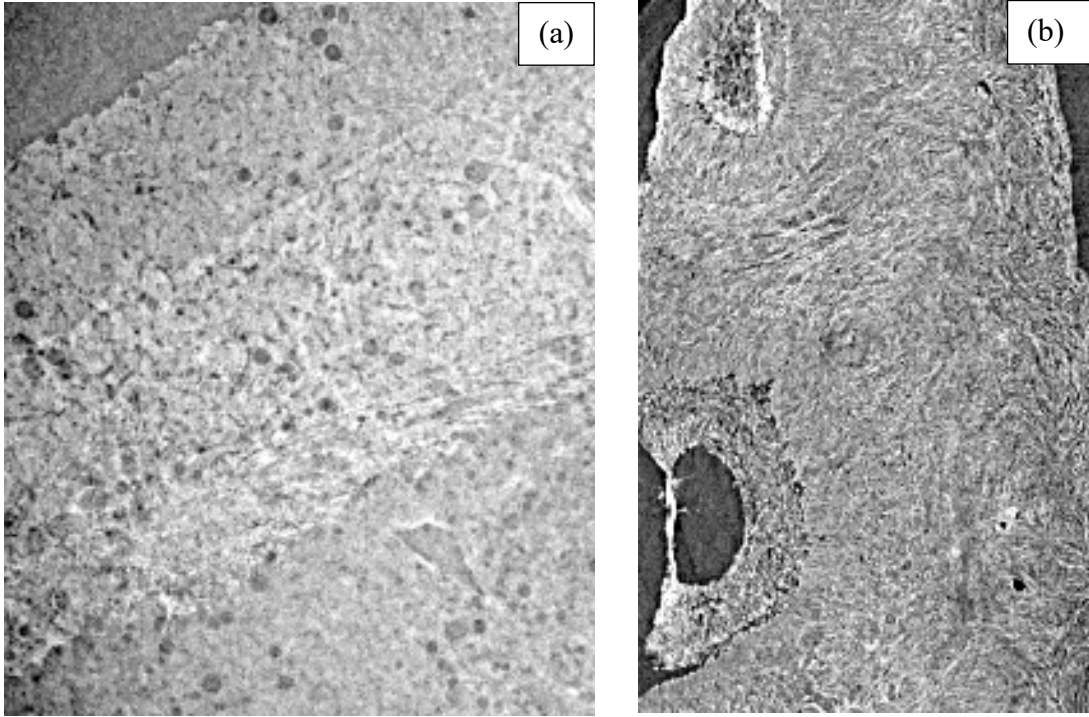


Figure 1: (a) An axial slice of a human liver sample with steatosis included in ethanol. The dark circles are the lipidic aggregates. (b) An axial slice of a bovine ovary sample included in paraffin. Follicles are recognisable on the left-hand side.